

Vein of Galen aneurysmal malformation in a neonate presenting with congestive heart failure

Vein of Galen aneurysmal malformation

Rasime Pelin Kavak, Meltem Özdemir, Önder Eraslan
Department of Radiology, University of Health Sciences, Dışkapı Yıldırım Beyazıt Training and Research Hospital, Ankara, Turkey

Abstract

Vein of Galen aneurysmal malformation is a rare complex vascular malformation that is characterized by arterial shunting into the median prosencephalic vein of Markowski, the embryonic precursor of the Galen vein. It occurs in less than 0.004% of deliveries. The disorder is classified as choroidal, mural, and mixed types. In most cases, it can be correctly diagnosed by prenatal ultrasonography performed in the third trimester. Herein, we present a case of choroidal VGAM who had not been evaluated by prenatal US, presented with severe heart failure in the early neonatal period, and died during the first days of life because of circulatory impairment.

Keywords

Vein of Galen; Malformation

DOI: 10.4328/ACAM.20070 Received: 2019-11-01 Accepted: 2019-11-09 Published Online: 2020-01-26 Printed: 2020-07-01 Ann Clin Anal Med 2020;11(4):340-342

Corresponding Author: Rasime P Kavak, University of Health Sciences, Dışkapı Yıldırım Beyazıt Training and Research Hospital, Department of Radiology, Ankara, Turkey

E-mail: drpelindemir6@hotmail.com P: +90 539 8440544

Corresponding Author ORCID ID: <https://orcid.org/0000-0001-9782-0029>

Introduction

Vein of Galen aneurysmal malformation (VGAM), also referred to as median prosencephalic arteriovenous fistula, is a rare vascular abnormality that occurs in less than 0.004% of deliveries [1]. While it constitutes less than 1-2% of all intracranial vascular malformations, it accounts for about 30% of cerebral vascular malformations presenting in childhood. VGAM is generally classified according to the Lasjaunias system which separates VGAMs into choroidal and mural types based on the number and origin of the feeding arteries. The choroidal type is characterized by high output heart failure and tends to present in the neonatal period whereas the mural type typically presents later in infancy with hydrocephalus [2]. It has been reported that 26.8% of all VGAMs are of choroidal type, 29.3% are of mural type, and 31.7% are of mixed type [3]. In most cases, VGAM can be correctly diagnosed by prenatal ultrasonography (US) performed in the third trimester. Thus, prenatal indicators of poor results in terms of mortality and brain injury can be detected before birth [4]. Herein, we present a case of choroidal VGAM who had not been evaluated by prenatal US, presented with severe heart failure in the early neonatal period, and died during the first days of life because of circulatory impairment.

Case Report

A term girl was born by normal vaginal delivery following an uncomplicated pregnancy. She was the first child of a 20-year-old mother. The mother had never undergone a US examination during pregnancy. There was no consanguineous marriage and no remarkable feature in family history. Cyanosis developed within the first hour after birth. A high cardiac murmur, venous neck pulsations, decreased peripheral pulsations, increased head circumference and hepatomegaly were detected on physical examination. Upon the suspicion of congenital heart disease, the patient was immediately transferred to the neonatal intensive care unit and intubated. Chest X-ray revealed an enlarged heart and echocardiography showed a dilated right ventricle with a normal heart structure. Increased pulmonary arterial pressures, patent foramen ovale, dilated superior vena cava, and retrograde diastolic flow in the descending aorta were also detected on echocardiography. A brain magnetic resonance imaging (MRI) was then performed. Vein of Galen aneurysmal malformation (VGAM) with characteristic multiple feeding arteries, an enlarged median prosencephalic vein and a persistent falcine draining sinus were evident on both conventional MRI (Figure 1) and magnetic resonance angiography sections (Figures 2 and 3). The neonate gradually became tachypneic over the first few days and recurrent seizures developed on the 5th day after birth. Antiepileptic drugs with medical treatment protocol for heart failure were applied. And an immediate endovascular embolization was decided. However, the patient showed signs of cardiac decompensation despite cardiac failure therapy and died on the 6th day of her life.

Discussion

VGAM is a complex vascular malformation that develops at 6-11th weeks of gestation and leads to arterial shunting into the median prosencephalic vein of Markowski, the embryonic

precursor of the Galen vein. This abnormal connection prevents the regression of the embryonic vein and restrains the development of the vein of Galen. The choroidal type VGAM is characterized by numerous arterial feeders including, choroidal, pericallosal, and thalamoperforating branches. In cases with high-flow fistulous connections, the disorder may cause high-

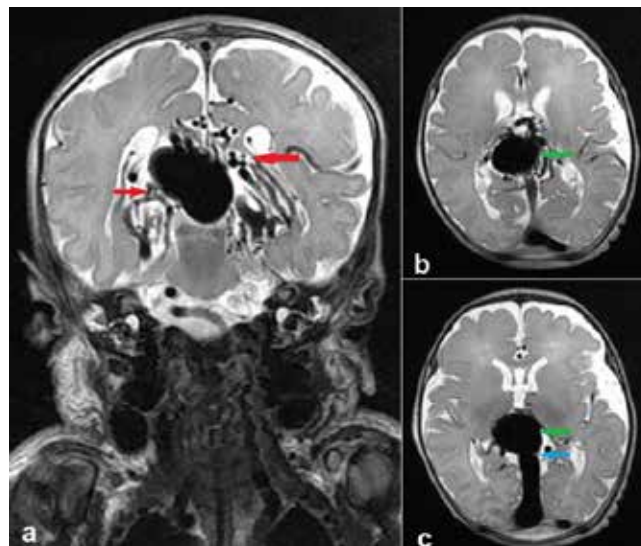


Figure 1. Coronal (a) and axial (b and c) T2-weighted magnetic resonance images demonstrating the Vein of Galen aneurysmal malformation. The feeders of arteriovenous fistulas (red arrows), dilated median prosencephalic vein (green arrow) and persistent falcine draining sinus (blue arrow) are clearly seen.

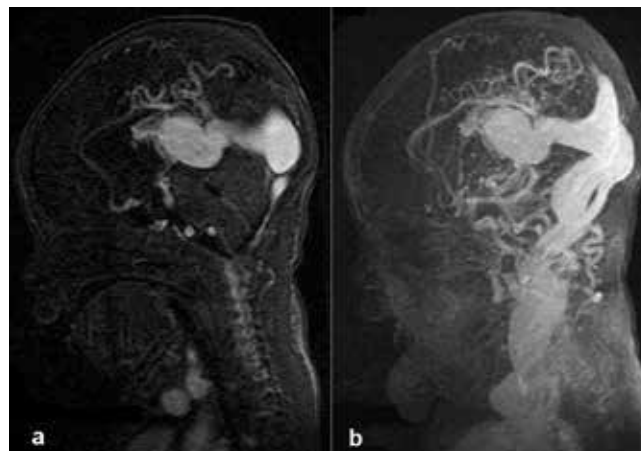


Figure 2. Coronal magnetic resonance angiography image showing dilated arterial feeders and highly enlarged median prosencephalic vein as the characteristics of Vein of Galen aneurysmal malformation.

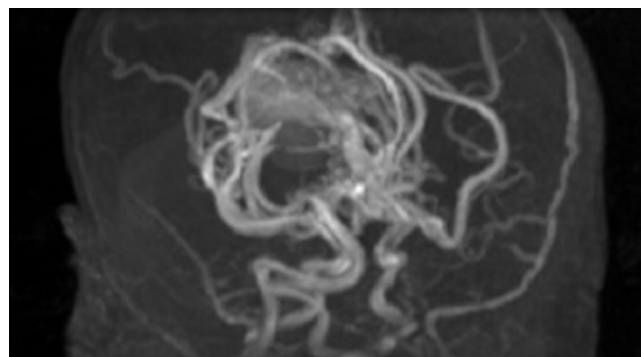


Figure 2. Sagittal magnetic resonance angiography images showing dilated choroidal feeders from the cerebral circulation and highly enlarged median prosencephalic vein as the characteristics of Vein of Galen aneurysmal malformation. Note the severe enlargement of venous sinuses as well as jugular veins.

output heart failure in the early neonatal period and may present at the extreme end that presents early after birth and necessitates urgent treatment [2].

Owing to the recent advances in US technology, the earlier recognition and characterization of fetal anomalies such as VGAM enabled the delivery of cases that would otherwise deteriorate over the last few gestational weeks. In their recent study, Paladini et al. described the poor prenatal prognostic variables for VGAM and proposed a flowchart for obstetric management of these cases on the basis of prenatal US and MRI findings [4]. They identified major brain lesions, tricuspid regurgitation, and VGAM volume $\geq 20000\text{mm}^3$ as poor prenatal prognostic variables. And they specified VGAM volume $\geq 40000\text{mm}^3$ as indicative of the need for planned early delivery. In the past, the treatment of VOGMs was neurosurgical, but the results were rather poor. Fortunately, novel endovascular approaches combined with optimized perinatal intensive care management over the last few years have increased the likelihood of successful VGAM treatment [5-8]. Endovascular treatment facilitates selective embolization of feeding arteries and allows targeted treatment that may be performed in multiple phases. The employment of dual lumen balloon catheters, coils, and liquid embolics has allowed effective treatment of this disorder and obviously decreased mortality [7]. Further, a recent report has introduced the application of targeted neonatal echocardiography for use in the management of patients with VGAM. It has been reported that this method promises to guide treatment decisions and allow controlled endovascular embolization in eligible candidates [8].

We presented a case of an unfortunate newborn who had not been prenatally diagnosed and presented with severe heart failure early after birth. The VGAM in our patient was of choroidal type with a rather high number of feeding arteries and presented as high-output heart failure. Moreover, the symptoms of our patient appeared at a very early stage, which is defined as a poor prognostic indicator [2]. The unfortunate association of choroidal type VGAM with very early-onset severe heart failure and the lack of postnatal emergency interventions due to lack of prenatal diagnosis explains why this patient's clinical course rapidly deteriorated and resulted in death.

Conclusion

Despite impressive advances in imaging technologies, treatment approaches and intensive care facilities in recent years, VGAM remains a highly lethal disease in cases with a high number of feeding arteries. Diagnosis of the disease by prenatal ultrasonography performed in the last trimester and correct intervention in high-risk cases at the right time will be beneficial in decreasing mortality.

Scientific Responsibility Statement

The authors declare that they are responsible for the article's scientific content including study design, data collection, analysis and interpretation, writing, some of the main line, or all of the preparation and scientific review of the contents and approval of the final version of the article.

Animal and human rights statement

All procedures performed in this study were in accordance with the ethical standards of the institutional and/or national research committee and with the 1964 Helsinki declaration and its later amendments or comparable ethical standards. No animal or human studies were carried out by the authors for this article.

Conflict of interest

None of the authors received any type of financial support that could be considered potential conflict of interest regarding the manuscript or its submission.

References

1. Brinjikji W, Krings T, Murad MH, Rouchaud A, Meila D. Endovascular treatment of vein of Galen malformations: a systematic review and meta-analysis. *AJNR Am J Neuroradiol*. 2017;38(12):2308-14.
2. Mortazavi MM, Griessenauer CJ, Foreman P, Bavarsad Shahripour R, Shoja MM, Rozzelle CJ, et al. Vein of Galen aneurysmal malformations: critical analysis of the literature with proposal of a new classification system. *J Neurosurg Pediatr*. 2013;12(3):293-306.
3. Spada C, Pietrella E, Caramaschi E, Bergonzini P, Berardi A, Lucaccioni L, et al. Heart failure caused by VGAM: a lesson for diagnosis and treatment from a case and literature review. *J Matern Fetal Neonatal Med*. 2019;18:1-7.
4. Paladini D, Deloison B, Rossi A, Chalouhi GE, Gandolfo C, Sonigo P, et al. Vein of Galen aneurysmal malformation (VGAM) in the fetus: retrospective analysis of perinatal prognostic indicators in a two-center series of 49 cases. *Ultrasound Obstet Gynecol*. 2017;50(2):192-9.
5. Puvabanditsin S, Mehta R, Palomares K, Gengel N, Ferrucci Da Silva C, Roychowdhury S, et al. Vein of Galen malformation in a neonate: A case report and review of endovascular management. *World J Clin Pediatr*. 2017;6(1):103-9.
6. Sivasankar R, Limaye US, Wuppapapati S, Shrivastava M. Endovascular Management of Vein of Galen Aneurysmal Malformations: A Retrospective Analysis over a 15-Year Period. *J Vasc Interv Neurol*. 2019;10(3):23-29.
7. Wagner KM, Ghali MGZ, Srinivasan VM, Lam S, Johnson J, Chen S, et al. Vein of Galen Malformations: The Texas Children's Hospital Experience in the Modern Endovascular Era. *Oper Neurosurg (Hagerstown)*. 2019;17(3):286-92.
8. Giesinger RE, Elsayed YN, Castaldo MP, McNamara PJ. Targeted Neonatal Echocardiography-Guided Therapy in Vein of Galen Aneurysmal Malformation: A Report of Two Cases with a Review of Physiology and Approach to Management. *AJP Rep*. 2019;9(2):e172-e6. DOI: 10.1055/s-0039-1688765

How to cite this article:

Rasime Pelin Kavak, Meltem Özdemir, Önder Eraslan. Vein of Galen aneurysmal malformation in a neonate presenting with congestive heart failure. *Ann Clin Anal Med* 2020;11(4):340-342